



A Case Report on Wart Treated Successfully by Individualized Homoeopathic Medicine

Kanchan Rathore

Department of Pediatrics, Homoeopathy University, Jaipur, India

Email address:

rathoredrkanchan@gmail.com

To cite this article:

Kanchan Rathore. A Case Report on Wart Treated Successfully by Individualized Homoeopathic Medicine. *International Journal of Homeopathy & Natural Medicines*. Vol. 9, No. 1, 2023, pp. 1-5. doi: 10.11648/j.ijhnm.20230901.11

Received: August 5, 2022; **Accepted:** August 23, 2022; **Published:** March 20, 2023

Abstract: Verrucae (warts) are the benign epidermal proliferative lesions that occur on skin and the adjacent mucosal membrane, caused by the Human Papilloma Virus (HPV) infection. Filiform warts on the face are more difficult to treat. There have been various conventional methods for treatment of such warts but it has its own pros and cons. Homeopathy here plays a vital role in treating these warts permanently with help of homeopathic individualized medicines. These medicines are selected on the basis of the general characteristic and peculiar symptoms of the patient. Here in this article the effectiveness of a well selected individualized homoeopathic medicine *Lycopodium Clavatum* has been explained through a case report. A male of 30 years with multiple filiform warts on the face due to change of place and environment of his residence reported to the OPD and was prescribed Homoeopathic medicine *Lycopodium Clavatum 30C* on the basis of totality of symptom which resolved those multiple warts on his face within a month with no reappearance of similar warts. This case report with photographic evidence shows the effectiveness of *Lycopodium clavatum 30C* in cases of filiform warts. Along with these warts the complaint of constipation was also relieved which was considered while selecting the medicine. thus proving that when homoeopathic medicines are selected properly they cure the individual as a whole.

Keywords: Human Papillomavirus, Filiform Warts, Individualization, Homoeopathy, *Lycopodium Clavatum*

1. Introduction

Warts are common, benign, epidermal lesions caused by human papillomavirus infection. They can appear anywhere on the body in a variety of morphologies. There are more than 100 types of HPV classified based on the type of virus, mode of entry, and immune status of host. The clinical disease depends on the type of HPV causing the same. Nongenital warts are most frequent in children and young adults (up to 10%), and are transmitted through direct skin-to-skin contact and autoinoculation. Warts are usually self limited but may be treated by destructive methods (eg, excision, cautery, cryotherapy, liquid nitrogen) and topical or injected agents. Filiform warts are long, narrow, frond-like growths, usually located on the eyelids, face, neck, or lips. They are usually asymptomatic. Diagnosis is by examination [1, 2].

Lycopodium is antipsoric, anti-syphilitic and anti-sycotic, and its sphere is broad and deep. Hahnemann brought it into use and developed its power by attenuation. It is a monument

to Hahnemann. *Lycopodium clavatum* is a spore-bearing vascular plant, growing mainly prostrate along the ground with stems up to 1 m (39 in) long; the stems are much branched, and densely clothed with small, spirally arranged microphyll leaves. It enters deep into the life, and ultimately changes in the soft tissues, blood-vessels, bones, liver, heart, joints. The tissue changes are striking; there is tendency to, necrosis, abscesses, spreading ulcers and great emaciation, has played a major role in treatment of Warts since the time of Dr Samuel Hahnemann [3].

Homeopathy is a system of medicine based fundamentally on the 'Principle of Similars': a substance capable of causing symptoms of illness in a healthy subject can be used as a medicine to treat similar patterns of symptoms experienced by an individual who is ill; homeopathic medicines are believed to stimulate a self-regulatory healing response in the patient. In *individualised homeopathy*, typically a single homeopathic medicine is selected on the basis of the 'total symptom picture' of a patient, including his/her mental, general and constitutional type [4, 2, 5].



Figure 1. *Lycopodium Clavatum* Plant.

2. Case Report

Patient History: A male patient aged 30 years reported on 09 March 2022 to Dr MPK Homoeopathic Medical College Hospital & Research Center (Under Homoeopathy University) Jaipur, Rajasthan, India, Outpatient Department with complaints of multiple filiform warts on the right side of his face from the last 15 days. This appeared to him when he went to stay at Jaisalmer for 15 days due to some office work (Figures 2 & 3). First there were only 2-3 warts then it went on increasing in size and number day by day. On general examination, his appetite was satisfactory. Desire for hot food. Bladder habits were normal, Had a sound sleep pattern. Patient suffered from constipation whenever he was away from his village, he also has fullness in abdomen with flatulence. Patient was thermally hot.

3. Clinical Examination

On examination, there were multiple long narrow frond-like projections on the beard area extended from skin with typical digitate appearance which is the characteristic feature of filiform warts (Figures 2 & 3). He was otherwise healthy and there was no history related to immunodeficiency in the past [6].

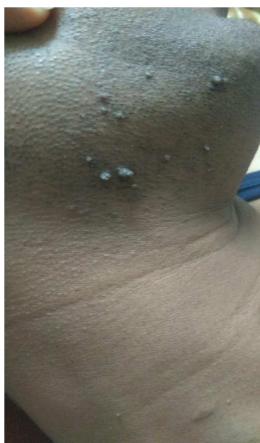

Figure 2. 12-13 filiform wart on region of whisker on right side of face (Lateral View).

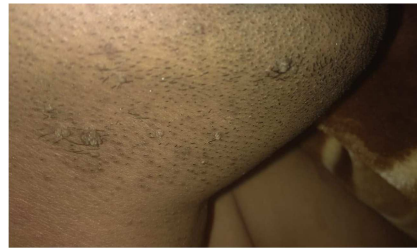

Figure 3. 12-13 filiform wart (Digitations are seen clearly) on right whisker region of face (Closer View).

4. Case Analysis

In this case, local signs and symptoms considered for repertorisation were filiform warts, warts on face, beard, desire for hot food, constipation when away from home, fullness in abdomen with flatulence [7]. Repertorisation was done with help of hompath software (Figure 4). The first three medicines with higher score were as follows in their descending order: *Lycopodium Clavatum*, *Thuja*, *Sepia*.

Lycopodium Clavatum -Affections are generally on right side of body, Suited to complex pale, dirty; unhealthy skin, Constipation when away from home, Excessive accumulation of flatulence, he feels bloated, The face is often covered with copper-colored eruptions, such as we find in syphilis.

Thuja - The general appearance of the Thuja subject, if he has a characteristic picture, is that of a waxy, shiny face, it looks as if he had been smeared over with grease; The skin looks unhealthy everywhere about the body and there is a copious sweat on first going to sleep. The tendency of the Thuja patient is to throw out wart-like excrescences which are soft and pulpy and very sensitive, they burn, itch and bleed easily when rubbed the clothing. Horny excrescences that form on the hands and split open form upon a pedicle and crack around the base. Cauliflower excrescences upon the cervix uteri, about the anus, about the labia majora and mucous membranes generally. Horny excrescences, more upon the skin. Warts of a brownish color, especially if upon the abdomen the body; great brown spots, like liver spots, form upon the abdomen. Has a specific antibacterial action, as in gonorrhoea and vaccination.

Sepia- Warts: on neck with horny excrescences in center; small, itching, flat on hands and face; large hard seed warts; dark color and painless; (large horny wart on abdomen). Sepia has jaundice, yet this peculiar sallowness is a waxy, anemic appearance, mottled with yellow, a yellow, sallow tint across the nose and the cheeks described as a yellow saddle across the nose and down the sides of the face. It is also common for the whole face to be covered with enormous freckles, great brown patches as in pregnancy, brown spots on the cheeks, brown warts, warts that have been red or pink become pigmented; liver spots on the face, chest, and abdomen [8-10].

5. Intervention

Lycopodium clavatum 30C- medicated on 30 sized

globules were dispensed single dose with Placebo dose three times a day for 1 week on the basis of totality of symptoms.

The patient was advised to shave after 1 week with a sterile blade and razor with care and a healthy diet regularly [11].

5.1. Repertorisation Sheet

Repertorisation Sheet - Homopath WildfireIHMS LAN																
Physician Name : Dr. unit 2																
Patient Name :																
Reg. No. :																
Date : 04/08/2022																
Remedy	Lyc	Sep	Thuj	Nux-v	Alum	Nat-m	Kali-c	Graph	Hep	Ph-ac	Phos	Rhus-t	Sil	Sulph	Ant-c	
Totality	14	12	11	10	9	9	8	8	8	8	8	8	8	8	8	7
Symptoms Covered	4	4	3	3	3	3	3	2	2	2	2	2	2	2	2	2
[Complete] [Face]Warts:Chin:	3	1	4	0	0	0	1	0	0	0	0	0	0	0	0	0
[Complete] [Abdomen]Fullness:	4	4	3	4	3	4	4	4	4	4	4	4	4	4	4	3
[Complete] [Rectum]Constipation:Home, when away from:	3	3	0	3	3	1	0	0	0	0	0	0	0	0	0	0
[Complete] [Skin]Warts, condylomata:	4	4	4	3	3	4	3	4	4	4	4	4	4	4	4	4

Figure 4. Repertorisation of the case with HOMPETH Software.

5.2. Follow up Sheet with Prescription and Justification

Table 1. First follow up.

DATE	SYMPTOM OF PATIENT	PRESCRIPTION	JUSTIFICATION
18/03/2022	Patient was feeling better, Stools were regular after 3rd day of starting medications, Gas in abdomen was decreased, No new wart appeared, 3-4 warts were decreased in size and number (Figures 5 & 6)	Rubrum 30/Single dose Phytum 30/3X 14 days	General symptoms were improved, Patient was feeling better, Number of warts were decreased so no medicinal dose required patient was given placebo [12]

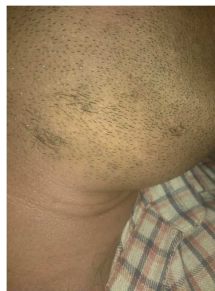

Figure 5. 8-9 Filiform warts on region of Whisker on right side of face (Closer view).

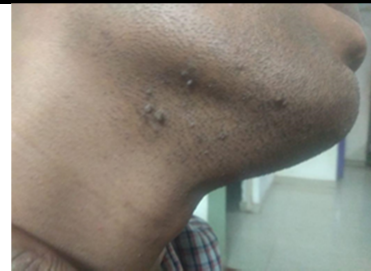

Figure 6. 8-9 Filiform warts on region of Whisker on right side of face (Lateral View).

Table 2. Second followup.

DATE	SYMPTOM OF PATIENT	PRESCRIPTION	JUSTIFICATION
28/03/2022	Patient was feeling good, Stools were regular, Gas in abdomen was absent, No new wart appeared, Only 6-7 warts were remaining, But there was increase in size of few warts (Figure 7)	Lycopodium Clavatum 30/Single dose Phytum 30/3X 14 days	General symptoms were improved, Patient was feeling good, Number of warts were decreased but there was increase in size of old warts so medicine dose was repeated

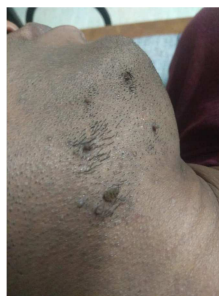

Figure 7. 6-7 warts with increase in size of wart on region of whisker on right side of face (Lateral View).

Table 3. Third follow up.

DATE	SYMPTOM OF PATIENT	PRESCRIPTION	JUSTIFICATION
08/04/2022	Almost all warts were almost healed, Stools were regular, Gas in abdomen was absent, No new warts appeared, Very small 1-2 warts were still present.(Figures 8 & 9)	Rubrum 30/Single dose Phytum 30/3X 14 days	General symptoms were improved, Patient was feeling healthy so placebo was given and patient was advised to follow up if there were any new wart or any aggravation in symptom otherwise after 1 month for general checkup [11]

Table 4. Follow up after 3 months of treatment.

DATE	SYMPTOM OF PATIENT	PRESCRIPTION	JUSTIFICATION
27/07/2022	Patient was feeling very happy as all his warts were completely healed and he was able to shave his beard very nicely Stools were regular, Gas in abdomen was absent, No new warts appeared. (Figure 10)	Rubrum 30/Single dose Phytum 30/3X 14 days	General symptoms were improved, Patient was feeling healthy so placebo was given and patient was advised to follow up if there is any new wart or any aggravation in symptom otherwise after 6 month for general checkup

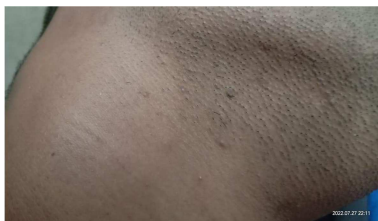


Figure 8. 1-2 small wart seen on region of whisker on right side of face (Closer view).

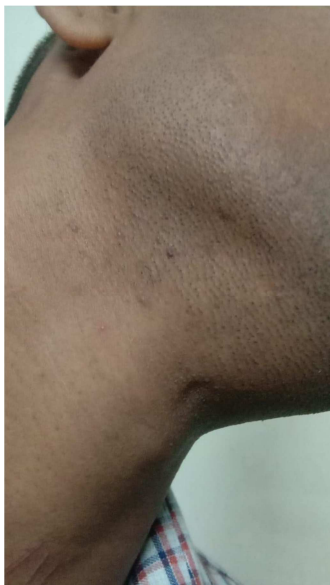

Figure 9. 1-2 wart seen on region of whisker on right side of face (lateral view).

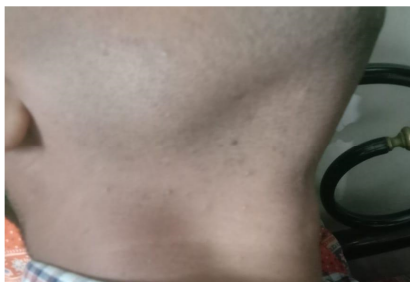

Figure 10. Clean shaved face with no new wart (Lateral view).

6. Discussion

Lycopodium clavatum 30c is an antimiasmatic constitutional Homoeopathic medicine which was selected for the patient on the basis of his constitution, his individual totality of symptoms. After 2 doses of lycopodium at an interval of 20 days the medicine has shown a wonderful result in the patient. This concludes that when homoeopathic medicines are selected and prescribed according to the cardinal principles of homoeopathy they heal the case completely and in a very fast and peaceful manner. Since there was no recurrence of warts this indicates that the cure was complete and permanent. Along with the chief complaint the associated complaint of constipation was also treated permanently by *Lycopodium Clavatum*.

It was also observed that the cost of 2 doses of *Lycopodium Clavatum* and Phytum is sufficient to treat multiple warts is economically cost effective for patient. Further, detailed clinical trials are needed to justified to explore its mechanism and optimize the dosage, which is an important step for an evidence-based healthcare system.

7. Conclusion

The well-chosen homeopathic remedy was very effective in this case of multiple warts on face; the patient reported reduction of symptoms along with improved general well-being. This concludes that the Individualized homeopathic treatment plays a very important role in such cases. Further, study is suggested for evaluating a larger spectrum of remedies in treating cases of warts.

References

- [1] Amuthan, A., 2022. [online] Ayurvedjournal.com. Available at: <https://www.ayurvedjournal.com/JAHM_202061_04.pdf> [Accessed 3 August 2022].
- [2] Biswas B, Roy PS, Mandal S, Roy P. Four cases of warts treated by individualized homoeopathic medicine - a clinical case study. J Intgr Stand Homoeopathy 2022; 5: 9-18.

- [3] Shaikh, Md Ismail. (2016). Case studies for treatment of warts with Homoeopathy. Indian Journal of Research in Homoeopathy. 10. 272. 10.4103/0974-7168.194342.
- [4] Oza, PiyushMahendra. (2016). Homeopathic management of warts. Indian Journal of Drugs in Dermatology. 2. 45. 10.4103/2455-3972.184085.
- [5] Mathie, R. T., Ramparsad, N., Legg, L. A. *et al.* Randomised, double-blind, placebo-controlled trials of non-individualised homeopathic treatment: systematic review and meta-analysis. *Syst Rev* 6, 63 (2017). <https://doi.org/10.1186/s13643-017-0445-3>
- [6] Ghadgepatil, S. S., Gupta, S., & Sharma, Y. K. (2016). Clinicoepidemiological Study of Different Types of Warts. *Dermatology Research and Practice*, 2016, 1–4. <https://doi.org/10.1155/2016/7989817>
- [7] Kent, J. and Vermeulen, F., 1988. *Materia medica*. Rijswijk: Elmar, p.lycopodium clavatum.
- [8] Allen, H., 1990. Keynotes and characteristics with comparisons of some of the leading remedies of the materia medica with bowel nosodes. New Delhi: B. Jain, pp. Pg 171-172.
- [9] William BOERICKE, M. D. Homeopathic Materia Medica.
- [10] Clarke, J. H. (1955). *A dictionary of practical materia medica* (3rd ed.). Homoeopathic Pub. Co.
- [11] Dhawale, M. L. (1967). *Principles & Practice of Homoeopathy. law of minimum dose* B Jain Publishers Pvt Ltd.
- [12] Kent, J. T. (2000). *Lectures on Homoeopathic Philosophy With Word Index* (Large Print ed.). B Jain Pub Pvt Ltd.